

CASE STUDY

- 100% WOUND REDUCTION
- TOTAL HEALING IN 26 WEEKS
- 11 ACTIGRAFT APPLICATIONS

PATIENT:

57 Year Old, Male

PAST MEDICAL HISTORY:

severe PVD, Diabetes mellitus type 2, arterial insufficiency, severe COPD, above knee amputation right leg, post CVA, Coronary Bypass, recovered from COVID 19, Renal Insufficiency, Upper gastrointestinal bleeding

WOUND HISTORY:

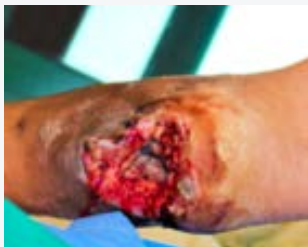- Pressure ulcer on left heel with exposed bone
- Osteomyelitis (treated). Post partial calcalectomy due to gangrene
- Candidate for amputation- refused

PAST TREATMENTS:

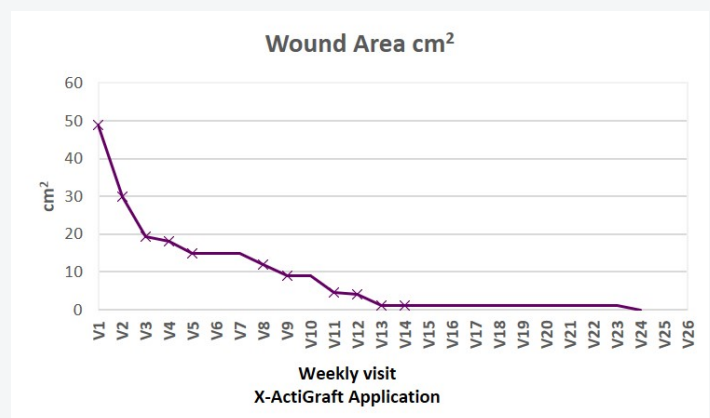
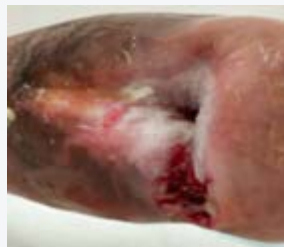VAC- no improvement; partial calcalectomy, advanced dressings, ultrasonic debridement

ACTIGRAFT TREATMENT PROGRESSION:

Day 0



Day 166



V=Weekly Application

OFFLOADING:

None